

Case report

Surgical treatment of stress fracture of the scaphoid of an adolescent gymnast

Tokuyoshi Yamagiwa, Hiroyuki Fujioka ✉, Hiroaki Okuno, Masaki Tomatsuri, Kenjiro Tsunemi, Juichi Tanaka and Shinichi Yoshiya

Department of Orthopaedic Surgery, Hyogo College of Medicine, Nishinomiya, Japan

Abstract

Stress fracture of the carpal scaphoid is very rare. We present stress fracture of the scaphoid in an adolescent gymnast who was treated with internal fixation.

Key words: Stress fracture, scaphoid, gymnast.

Introduction

Stress fractures are partial or complete fractures of a bone resulting from an inability to withstand stress applied in a repeated manner (Jones, 2006). In the upper extremity, stress fracture of the first rib, the olecranon, and the metacarpal bone have been reported as sports related injury (Jones, 2006). In the present report, we present stress fracture of the carpal scaphoid in an adolescent gymnast who was treated with internal fixation. The patient and his families were informed that data from the case would be submitted for publication and gave their consent.

A case report

An eighteen-year-old man, who is a gymnast ranked at the Japanese National Team level, felt pain over the dorsum of the right wrist when he was doing handstands and pushing-up activities on the floor in the absence of any major traumas or identifiable causes. Wrist pain increased gradually and the patient visited us. Palmar flexion of the wrist was not limited but dorsal flexion was limited to 70

degree because of wrist pain. Tenderness was detected at the anatomical snuff box. On the radiograph at the first visit, a fracture line was not detected and the osteophyte was observed, however, on magnetic resonance imaging (MRI), the low-intensity on the T1-weighted image and the high-intensity on T2-weighted image were detected at the waist of the scaphoid (Figure 1). We suspected stress fracture of the scaphoid and instructed the patient to immobilize the wrist with a wrist brace and to reduce the sports activities using the right hand for two months. However, his wrist pain was not relieved by this conservative treatment and a follow-up radiograph of the wrist clearly revealed a displaced fracture line in contrast with the radiographs from the first visit (Figure 2A). Therefore, we treated the patient surgically.

A 1 cm-skin incision was made over the scaphotrapezoid joint at the volar aspect of the wrist and the distal portion of the scaphoid was exposed. A Kirschner wire (1.0 mm in diameter) at the optimal position of the scaphoid under fluoroscope without using the jig. After removing the Kirschner wire, the drill hole was made in the scaphoid using the track made by the Kirschner. The fracture site was not exposed and a Herbert screw (Zimmer, U.S.A.) was inserted to fix the fracture site of the scaphoid under fluoroscope. After two weeks immobilization with a thumb spica cast, the patient started the range of motion exercise of the wrist and the physical exercise. At postoperative 2 months, fracture line of the scaphoid disappeared suggesting fracture union on the

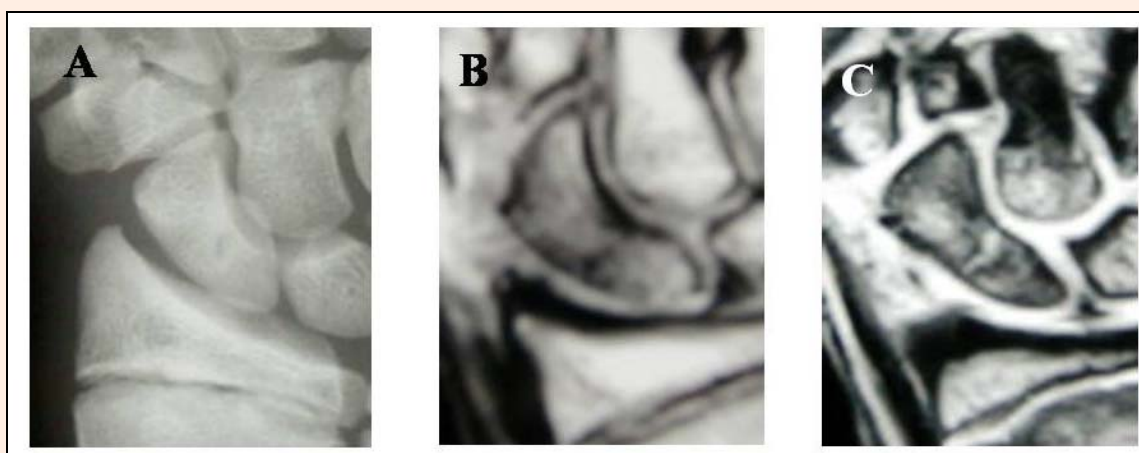


Figure 1. Radiograph (A) and MRI (B, C) of the right wrist at the first visit. On the anteroposterior view of the radiograph, the fracture at the waist of the scaphoid did not detected and osteophyte formation of the radial styloid process was observed (A). The low-intensity on the T1-weighted image (B) and the high-intensity on T2-weighted image (C) on MRI were observed at the waist of the scaphoid.

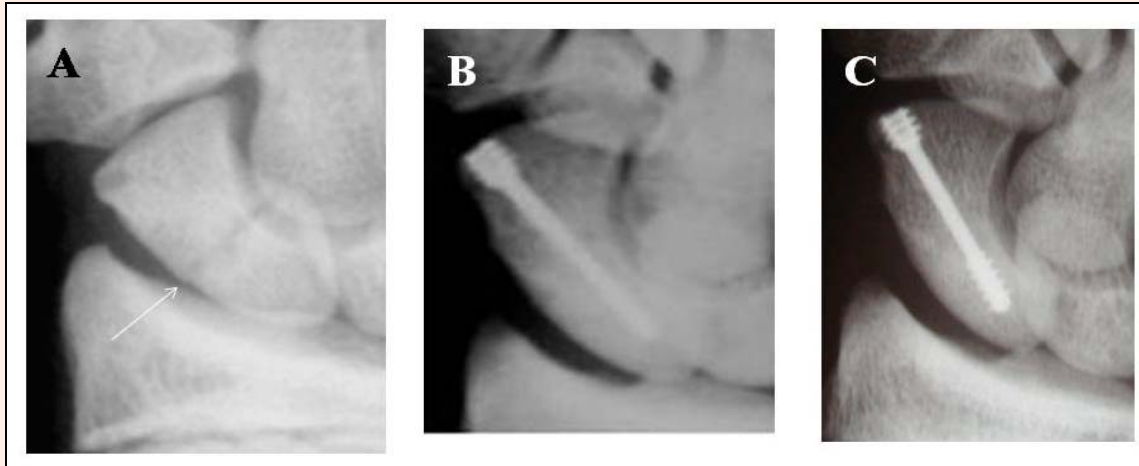


Figure 2. Radiographs before surgery (A), at postoperative two months (B), and at postoperative one year (C). A displaced fracture line (an arrow) was detected at the waist of the scaphoid (A). Union of the scaphoid was confirmed at postoperative 2 months and 1 year (B, C).

radiographs (Figure 2 B) and returned to the original activity level. At postoperative one year, union of scaphoid fracture was confirmed on radiographs (Figure 2 C). The patient could perform gymnastics without any complaints at the two year follow-up.

Discussion

Stress fracture of the carpal scaphoid is very rare disorder and have been only reported in gymnasts and a shot putter (Hanks et al., 1989; Mazzone and Pizzutillo, 1981). The upper extremities are used for weight-bearing in gymnastics unlike in other sports and the wrist, during gymnastic activities, is exposed to many different types of stress, including repetitive motion and high impact loading, and axial compression (Webb and Rettig, 2008). Hanks et al. suggested that stress fracture of the scaphoid in nationally ranked gymnasts is caused by repeated dorsiflexion of the wrist such as the mechanism of the scaphoid impaction syndrome (Hanks et al., 1989). A recent biomechanical study of the wrist demonstrated that loading patterns at the wrist extension position are altered from that at the neutral position and that force transmission in the wrist extension position shifts radially, concentrating at the scaphoid (Majima et al., 2008). Excessive repetitive compressive loading forces to the scaphoid in the wrist extension position during the gymnastic activities may thus lead to the development of scaphoid stress fracture.

In the present report, the patient felt wrist pain when he was doing handstands and pushing-up activities on the floor without any specific trauma. When the patient initially visited our institution, a fracture line of the scaphoid was not detected on the radiographs but osteophyte at the radial styloid process was observed suggesting repetitive impaction at the radioscapoid joint. Moreover, MRI demonstrated changes of the intensity of the scaphoid bone suspecting stress fracture. Therefore, we diagnosed the patient with scaphoid stress fracture caused by excessive repetitive loads to the wrist during gymnastic activities.

Stress fractures of the carpal scaphoid in the previous reports have been successfully treated with immobilization (Hanks et al., 1989; Mazzone and Pizzutillo, 1981). In contrast, in the present case, we initially instructed the patient to immobilize the wrist with a wrist brace and to reduce sports activities using the right hand for two months, however, his wrist pain was not relieved and the displacement of the fracture site increased. Therefore, we concluded that conservative treatment in the present case might not be impossible and chose surgical treatment.

In the present report, the patient was adolescent and the growth plate of the distal radius was observed. To treat established scaphoid nonunion in skeletally immature patients, several reports recommend surgical treatment with internal fixation and bone grafting, because internal fixation with a screw for the scaphoid does not interfere scaphoid maturation (Mintzer et al. 1995; Toh et al. 2003). Therefore, we treated the adolescent patient surgically with internal fixation using a headless screw through the small skin incision.

Internal fixation of scaphoid fracture through a small incision without open reduction of the fracture site of the scaphoid has been reported (Haddad and Goddard, 1998; McQueen et al., 2008). Recently, several cannulated headless screw systems using a guide wire for scaphoid fixation have been developed and available. Percutaneous scaphoid fixation for acute fractures with a headless screw, which has a cannulated system using a guide wire to ensure a better position, obtained satisfactory results and rapid functional recovery (McQueen et al., 2008). In the present report, we used the conventional Herbert screw to fix the fracture site through a small incision, however, we would like to use the headless screw with a cannulated guide wire system when we have a chance to treat the similar case in future.

Conclusion

The physicians should be aware of the risk of stress fracture of the scaphoid in gymnast. We recommend surgical treatment of internal fixation with a screw through a small incision, which is one of the good options for stress frac-

ture of the scaphoid in order to return to the original sports activity quickly.

References

- Haddad, F.S. and Goddard, N.J. (1998) Acute percutaneous scaphoid fixation A pilot study. *Journal of Bone Joint Surgery British Volume* **80**, 95-99.
- Hanks, G.A., Kalenak, A., Bowan, L.S. and Sebastianelli, W.J. (1989) Stress fractures of the carpal scaphoid. A report of four cases. *Journal of Bone and Joint Surgery American Volume* **71**, 938-941.
- Jones, G.L. (2006) Upper extremity stress fractures. *Clinical Sports Medicine* **25**, 159-174.
- Majima, M., Horii, E., Matsuki, H., Hirata, H. and Genda, E. (2008) Load transmission through the wrist in the extended position. *Journal of Hand Surgery American Volume* **33**, 182-188.
- Mazzone, M. and Pizzutillo, P.D. (1981) Stress fracture of the scaphoid waist. A case report. *American Journal Sports Medicine* **9**, 268-269.
- McQueen, M.M., Gelbke, M.K., Wakefield, A., Will, E.M. and Gaebler, C. (2008) Percutaneous screw fixation versus conservative treatment for fractures of the scaphoid. A prospective randomized study. *Journal of Bone and Joint Surgery British Volume* **90**, 66-71.
- Mintzer, C.M., Waters, P.M. and Simmons, B.P. (1995) Nonunion of the scaphoid in children treated by Herbert screw fixation and bone grafting. A report of five cases. *Journal of Bone and Joint Surgery British Volume* **77**, 98-100.
- Toh, S., Miura, H., Arai, K., Yasumura, M., Wada, M. and Tsubo, K. (2003) Scaphoid fractures in children. Problems and treatment. *Journal of Pediatric Orthopaedics* **23**, 216-221.
- Webb, B.G. and Rettig, L.A. (2008) Gymnastic wrist injuries. *Current Sports Medicine Reports* **7**, 289-295.

Key points

- There is a risk of stress fracture of the scaphoid in gymnast.
- Internal fixation with a screw is one of the good options for stress fracture of the scaphoid.

AUTHORS BIOGRAPHY



Tokuyoshi YAMAGIWA

Employment
Assistant professor
Degree
MD
Research interest
Orthopaedics, Hand, Sports?
E-mail: yamagiwa@hyo-med.ac.jp



Hiroyuki FUJIOKA

Employment
Lecturer
Degree
MD
Research interest
Orthopaedics, Hand, Upper extremity, Sports, Basic research
E-mail: hfujioka@hyo-med.ac.jp



Hiroaki OKUNO

Employment
Assistant professor
Degree
MD
Research interest
Orthopaedics, Hand, Sports, Basic research.



Masaki TOMATSURI

Employment
Visiting lecturer
Degree
MD
Research interest
Orthopaedics, Hand, Pediatrics, Sports



Juichi TANAKA

Employment
Professor
Degree
MD
Research interest
Orthopaedics, Hand, Sports

Shinichi YOSHIYA

Employment
Professor, Chairman
Degree
MD
Research interest
Orthopaedics, Knee, Sports

✉ **Hiroyuki Fujioka**

Department of Orthopaedic Surgery, Hyogo College of Medicine, 1-1, Mukogawa-cho, Nishinomiya, 663-8501 Japan